Entomological Studies ISSN 3153-743X

Entomological Studies, 1: 67–78 (2026)
https://journal.entomologicalstudies.net
https://doi.org/10.5281/zenodo.22278367

ARTICLE

On the technique for the dissection of the genital structures of Lepidoptera

ANTON V. VOLYNKIN

African Natural History Research Trust, Street Court, Leominster, HR6 9QA, United Kingdom
✉ *anton.volynkin@anhrt.org.uk;* *https://orcid.org/0000-0001-9447-4925*

Received: 1 August 2026 | Accepted by S.Y. Huang: 18 August 2026 | Published online: 7 September 2026

Citation: Volynkin, A.V. (2026) On the technique for the dissection of the genital structures of Lepidoptera. *Entomological Studies*, 1, 67–78.

Abstract
The paper describes methods and techniques of preparation of the male and female genitalia of Lepidoptera with the aim of providing a practical guide for those who need to learn how to dissect genitalia for research or educational purposes.

Key words: dissection, Euparal, internal genitalia, male vesica, female bursa, maceration, microscopic slides, staining.

Introduction

Male and female genitalia structures are one of the most important characters used for identification of Lepidoptera and understanding their relationships. The examination of external male genitalia has a long tradition in lepidopterology, since Rambur (1838–1842) applied it to some European Hesperidae species. The examination of internal genitalia characters was first carried out by Janse (1932), who studied male vesicae of certain South African Noctuidae, but this method became widely adopted only in the second half of the 20th century. The approaches to genitalia preparation, including vesica eversion and slide mounting, were described by Hardwick (1950). Subsequently, the basics of the technique for vesica eversion and bursa inflation by syringe injection were redescribed by Lafontaine (1987), Lafontaine & Mikkola (1987), Bolte (1990), Dang (1993), and Fibiger (1997). A comprehensive review of eversion techniques in lepidopteran taxonomy was published by Mikkola (2007). Those publications are useful for general understanding of the methods but, unfortunately, contain too few minor but important details, which makes beginners struggle with the successful preparation of fine internal structures such as the vesica in males and the bursa copulatrix in females.

The present paper describes methods and techniques of lepidopteran genitalia preparation employed by its author, with the aim of providing a practical guide for those who need to learn how to dissect genitalia for research or educational purposes.

Since in most large museums and in a number of private collections the preferred method of storing genital preparations is mounting them on slides using a resin-based Euparal mountant, the present paper also contains a description of the approaches to mounting permanent genital preparations employed by the author. In addition to mounting on slides, genitalia may also be preserved in a micro vial with glycerol. Such storage allows rapid examination of genital structures from different angles; however, preparation for photography of the glycerol preparations takes more time and requires special approaches, a description of which is beyond the scope of the present paper.

Copyright: © Anton V. Volynkin. This is an open access article distributed under terms of the Creative Commons Attribution License (Attribution 4.0 International – CC BY 4.0).

Equipment

The **forceps** should be sensitive, with the finest possible sharpened tips that meet precisely when closed, enabling manipulation of the most delicate objects, including membranes.

A **dissecting needle** is convenient for holding a specimen by pressing it against a microscope slide.

Vannas scissors are used for cutting membranes and the ductus ejaculatorius. Straight scissors with the shortest possible blades (4–5 mm) are most suitable.

A **scalpel** may be used for transecting the ductus ejaculatorius in very small preparations, as well as for trimming excess membrane from the genitalia. For dissection of the genitalia, an ophthalmic scalpel with a small blade can be employed. Alternatively, a scalpel can be handmade from a dissecting needle or an insect pin by flattening its tip and sharpening the edge with a fine knife sharpener.

Syringes. Since different stages of dissection require operations first in water and then in alcohol, it is convenient to use two syringes containing water and isopropanol, respectively. Narrow Luer syringes of small volume (1 ml) with a plastic plunger tip are recommended, as the rubber tip is damaged by isopropanol and quickly deteriorates.

Syringe needles. For the vesica eversion, fine needles are required. The smallest gauge commercially available is 34G. The needle may be sharp or blunt. A sharp tip is usually too long for manipulation inside the phallus tube and may also damage the vesica. Therefore, its sharp point should be ground down and rounded using a knife sharpener. A blunt tip is also not very convenient for insertion into the phallus tube or for pressing against the opening of the ductus ejaculatorius (see below), so it is recommended to grind it obliquely and make its end conical with a knife sharpener. Operations with the knife sharpener must be carried out under a microscope, slowly and carefully, controlling every movement so as not to deform the needle orifice, which would render the needle unusable. Correcting the shape or enlarging the orifice may sometimes be possible using the fine tip of an entomological pin. It should be noted that the internal channel diameter of a 34G needle is very small; therefore, distilled water must be used for vesica eversion and for rinsing. Otherwise, the needle channel is quickly blocked by precipitated salts. In addition, the channel is sometimes blocked by microscopic plastic or cellulose fibres that regularly enter the water and alcohol containers from the external environment, so these chemicals require regular coarse filtration. In the event of channel blockage by fibres, it may be possible to clear it using a hair, manipulated with forceps under the microscope.

For cleaning the genitalia and the abdomen exoskeleton of scales and remnants of soft tissues, a fine **brush** of soft natural hair (e.g., squirrel) is usually used, cut short transversely. In addition to the brush, a more delicate tool with similar function can be used, which is handmade from a clipped small bird feather attached to a dissecting needle.

Pipettes are used for liquid handling, including Euparal.

Beakers or **Petri dishes** are used for rinsing preparations in water.

For storage and use of staining solutions, washing isopropanol, lactic acid, and pre-mounting Euparal, glass laboratory **staining blocks** with lids, glass laboratory **weighing bottles**, or small plastic jars with screw caps are used.

Chemicals

Alkali. A 10 % solution of KOH (potassium hydroxide) is used for dissolving soft tissues and softening the sclerotised parts of genital structures. NaOH (sodium hydroxide) has similar chemical properties; however, its use generates a large number of gas bubbles within the hollow structures of the genital apparatus, making NaOH less preferable.

Water. For primary rinsing, ordinary tap water is acceptable, but for preparing staining solutions and filling the syringe (see above), exclusively distilled water should be used.

Alcohol. Absolute isopropanol is used for dehydration, degreasing, and for inflating the vesica and bursa. For preparing the Eosin staining solution (see below), absolute ethanol is preferable because it dissolves the dye better.

Lactic acid is used to soften heavily sclerotised structures. As an alternative, acetic acid may be employed; however, it requires strict control of the treatment time because of its high activity, which rapidly thins the sclerotised structures and dissolves membranes, potentially leading to destruction of the preparation if overexposed. Acetic acid

also requires careful handling in a well-ventilated room owing to the risk of irritation to the preparator's eyes and respiratory tract.

Dyes. **(1) Eosin B and Eosin Y** (Caro 1892; Suvarna *et al.* 2013). These are the most applicable, interchangeable dyes, colouring cuticle and membranes red or orange-red, respectively. An alcoholic solution of Eosin is used for staining the phallus and abdomen, whereas an aqueous solution is better for the genital capsule (see below). Eosin is highly soluble in water and ethanol but much less so in isopropanol, which makes ethanol preferable for preparing the alcoholic staining solution, despite isopropanol being more effective for fixing the shape of the vesica and bursa. Usually, when preparing the solution casually, the amount of Eosin added is determined by eye through successive addition of small portions of crystals to the solvent, until the solution becomes deep red or deep orange. The staining time depends on the concentration of the solution. In the case of overstaining, excess Eosin is readily washed out with water. It should also be mentioned that during the first few days after mounting the genital slide, the stained preparation (especially thin membranous structures) noticeably fades. This is apparently due to the alcohol-solubility of Eosin, whereby part of the Eosin from the preparation dissolves in eucalyptol, which acts as a solvent in Euparal. For this reason, when using Eosin as a dye, one should aim for more intense staining of thin-walled membranous structures such as the vesica or bursa. **(2) Blue dyes**. In addition to subsequent fading of the preparation, the main disadvantage of Eosin is that it intensely stains both sclerites and thick-walled gelatinous structures, often found in the female bursa copulatrix and appendix bursae. In some cases, on an intensely Eosin-stained preparation it becomes impossible to determine the nature of darkly stained structures, which may be of high diagnostic significance. Therefore, for staining female genitalia that possess gelatinous structures, it is often better to use blue dyes, which stain membranous and gelatinous structures but leave sclerites naturally coloured. Blue dyes are also widely applicable for staining male vesicae because of the stability of their staining in Euparal. **(a) Chlorazol Black** (Cannon 1937; Baker 1941). This dye is most widely known and traditionally used for staining male vesicae and female bursae (Fibiger 1997; Kononenko 2010). Nevertheless, it is toxic and often stains membranes unevenly. To prepare the staining solution, a few drops of Chlorazol Black are dissolved in 30 % alcohol. Staining occurs rapidly; therefore, to avoid overstaining, the phallus/female genitalia should be placed in the staining solution for a short time (a few seconds). The time varies with the strength of the solution and must be determined experimentally, starting with a very short duration and then prolonging it if the staining is too weak. There is also a known method of staining the vesica and bursa by injecting the Chlorazol Black staining solution (analogous to blowing with absolute alcohol for inflating the vesica/bursa and fixing their shape) (Kononenko 2010). This approach should be applied with caution and using personal protective equipment because of the toxicity and permanence of Chlorazol Black. **(b) Evans Blue** (Evans & Schulemann 1914; Cooksey 2013). This dye is a more convenient and safer alternative to Chlorazol Black. Evans Blue is highly soluble in water but almost insoluble in alcohol, which makes staining more stable in Euparal. Staining of membranes with it proceeds rather quickly, and the staining approaches are generally similar to those for Chlorazol Black. Since staining is performed using an aqueous solution, voluminous structures such as the vesica and bursa often collapse. For this reason, after staining, the vesica or bursa should be rinsed and reinflated by prolonged injection of isopropanol, and the preparation placed in a container with absolute alcohol to prepare it for mounting on a slide. **(3) Combined use of Eosin and Evans Blue**. In some cases, Evans Blue stains membranes of different thickness unevenly (thicker areas remain lighter), and some weakly sclerotised structures remain unstained and poorly distinguishable against more intensely stained membranous areas. This can be avoided by combined, sequential staining of the preparation with both dyes. Disadvantages of this method include difficulties in processing photographs of genitalia stained in this way in a graphic editor if black-and-white illustrations need to be prepared. In addition, during dissection of the male genitalia of the same specimen, the thin-walled vesica can be stained with Evans Blue or a combination of Evans Blue and Eosin, while the genital capsule can be stained with Eosin alone.

Euparal. In modern entomology, Euparal is most often used as a mountant for permanent preparations; unlike the well-known Canada balsam, it does not contain toxic xylene as a solvent and is therefore safer. Nevertheless, it should be remembered that Euparal is flammable and an irritant, so it must be handled in a well-ventilated room and its contact with eyes and skin should be avoided. Euparal is readily soluble in isopropanol or ethanol but is hydrophobic, so the preparation must be dehydrated with 70–99% alcohol before being placed in Euparal. If water gets into Euparal, a dark, viscous suspension of minute water droplets forms, heavily contaminating the preparation.

Because of the hydrophobicity of Euparal, instruments must also be cleaned of it with alcohol and wipes before using them in water. Since alcohol strongly and rapidly thins Euparal, direct transfer of genitalia or abdomen from a container of alcohol into the mounting drop of Euparal on the slide should be avoided, as this leads to thinning of the Euparal and spreading of the drop over the slide, often resulting in collapse of voluminous structures such as the vesica or bursa. Instead, it is strongly recommended to first place the preparation in a pre-mounting container with Euparal, which absorbs excess alcohol.

Dissection

Maceration in alkali

The abdomen should be separated from the thorax using forceps and placed in a test tube with 10 % KOH solution, which is heated in a dry block heater or in a water bath to dissolve soft tissues and fat reserves. The duration of hot alkali treatment depends on the chosen temperature as well as on the size of the abdomen. Usually, at 85–90 °C, small abdomens are satisfactorily macerated within 6–8 minutes, medium-sized moth abdomens require 12–20 minutes of maceration, and larger ones 30–45 minutes. In some cases, a method of alkali treatment at a lower temperature is applied: 60 °C for 5–8 hours, or cold maceration at room temperature for 12–24 hours.

A high fat content in the abdomen also increases the duration of alkali treatment: female abdomens, which generally contain more fat than those of males, require more time. Similarly, longer treatment is required for abdomens of aphagous representatives of families such as Lasiocampidae, Cossidae, Notodontidae, some autumnal or spring Noctuidae, etc. Intermediate rinsing of the abdomen and replacement of the KOH solution can help reduce the maceration time.

The macerated abdomen is carefully rinsed free of alkali and remnants of soft tissues with water and placed in a drop of water on a microscope slide.

Dissection of male genitalia

Pull the genitalia outwards using forceps and a dissecting needle, and separate them by cutting (Fig. 1: a) or tearing (Fig. 1: b) the intersegmental membrane connecting the annulus (tegumen-vinculum complex) to the 7th abdominal segment.

Transect the ductus ejaculatorius close to its junction with the phallus using Vannas scissors or a scalpel (Fig. 2).

Separate the phallus from the genital capsule by one of two methods. (1) The preferred method is to pull the phallus in the caudal (posterior) direction (Fig. 3: a), withdrawing it from the phallocrypt and everting the latter like a stocking (Fig. 3: b). When performing this operation, care should be taken and it should only be attempted after the margins of the phallus and the anellus have been recognised, since an attempt to pull the phallus while inadvertently grasping the vesica instead of the sclerotised wall of the phallus usually damages the vesica, making its eversion impossible. (2) The simplest and most common method is to pull the phallus in the cranial (anterior) direction out of the genital capsule, which is held with forceps or pressed against the slide with a dissecting needle (Fig. 4). This tears the phallus off from the diaphragm together with the phallocrypt and manica, but may in some cases damage the anellus, which is undesirable if the latter bears any structures of diagnostic value.

Place the extracted phallus in a small drop of water on a separate microscope slide to evert the vesica by injection of distilled water.

For successful eversion of the vesica, the tip of the vesica ejaculatorius must be tucked inside the phallus tube. This can be done with the tip of a fine pin. It is also necessary that the vesica, or most of it, be located inside the phallus tube distal to the tip of the syringe needle. It can be pushed forward with the tip of the syringe needle or with the blunt tip of a finer pin (Fig. 5).

If the diameter of the phallus is larger than the diameter of the syringe needle, insert the latter into the phallus tube through the opening of the ductus ejaculatorius for injection (Fig. 6). If the diameter of the ductus ejaculatorius is smaller than that of the syringe needle, it is permissible to incise or tear the dorsal wall of the phallus tube caudal to the ductus ejaculatorius with the sharp tip of a fine pin (Fig. 7). It should be borne in mind that excessive pressure generated during the initial injection may rupture the wall of the main chamber or the proximal section of

the vesica, making further eversion problematic or even impossible. The risk of such damage is high if the vesica is long and tightly packed in a short phallus and/or bears numerous cornuti or scobinations that may be anchored in the folds of the vesica. Therefore, the injection must be carried out slowly and carefully, often in several stages, each time applying slight or moderate pressure and assessing how the vesica behaves inside the phallus tube. Begin with a slow injection from a position where the syringe needle is loose in the opening of the ductus ejaculatorius; excess pressure is then released by part of the jet escaping outwards, which may prevent accidental damage to the wall of the vesica or the phallus (Fig. 8). Usually the pressure generated in this way is sufficient to evert the main chamber of the vesica or to push the main part of the vesica forwards along the tube, often with eversion of the proximal section. Such displacement of the vesica allows the syringe needle to be inserted deeper into the phallus tube and the injection repeated, pressing the edges of the ductus ejaculatorius opening against the needle to reduce pressure loss. The edges can be pressed with forceps or with the fingers (provided the phallus is large enough and the preparator has sufficient skill). In many cases, to make all diverticula of the vesica fully expand, one must slowly press the syringe plunger for several seconds, maintaining a constant stream pressure. It is not uncommon that some diverticula have not fully expanded while the vesica ejaculatorius is already everted and alcohol flows freely through it, causing a strong loss of pressure inside the vesica chamber. Clamping the vesica ejaculatorius can help to expand the diverticula, as it raises the pressure inside the vesica and promotes eversion of the remaining structures. This can be achieved by clamping the vesica ejaculatorius itself with forceps (Fig. 9), or by wrapping it in the cranial direction and placing it against the wall of the phallus tube, thereby allowing the vesica ejaculatorius to be clamped together with the phallus during injection (Fig. 10). If an uneverted diverticulum is long and narrow (utricular) and bears one or more cornuti, sometimes the only way to spread it is to grasp the tip of the cornutus with forceps and mechanically pull it outwards; extreme care must be taken to avoid breaking or damaging the cornutus.

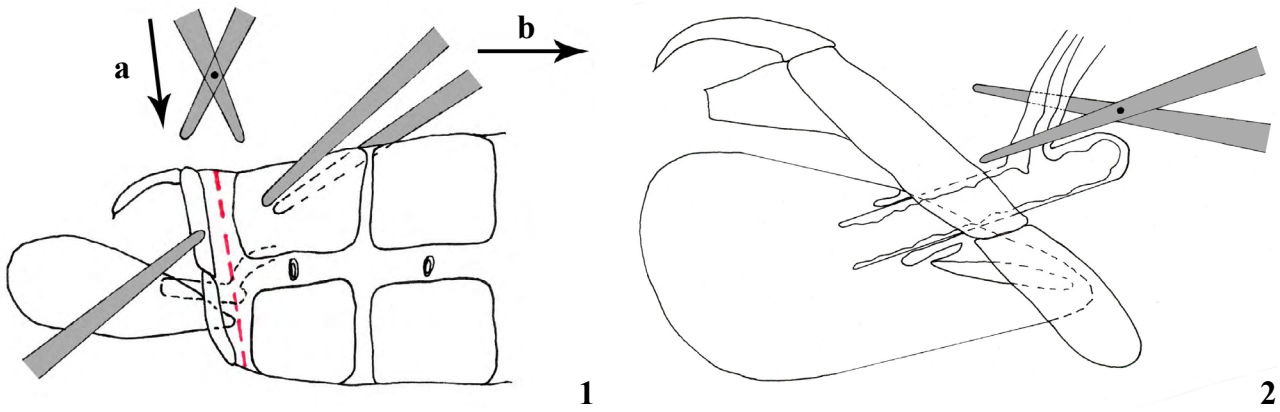

Figures 1, 2. Dissection of male genitalia. **1.** Separation of the male genitalia from the abdomen via cutting the membrane using Vannas scissors (a), or tearing it using forceps and a preparation needle pressing the genitalia against the slide (b). **2.** Cutting the ductus ejaculaorius using Vannas scissors.

If the phallus tube is too narrow to allow insertion of the syringe needle, it is often possible to evert the vesica by pressing the needle orifice against the opening of the ductus ejaculatorius and directing the water jet into the tube (Fig. 11). In some cases this is feasible if the phallus is held with the ductus ejaculatorius opening upwards and the needle orifice is pressed against it from above (Fig. 12). If the phallus is slender but the opening of its ductus ejaculatorius is located at or near the cranial end of the phallus, there is a chance to evert the vesica using a blunt syringe needle of larger diameter, inserting the phallus into the needle channel (Fig. 13) (Bolte 1990; Dang 1993).

A small phallus is difficult to hold with forceps, so it is more convenient to perform the eversion procedure without separating the phallus from the genital capsule (Fig. 14), subsequently extracting it together with the everted vesica in the caudal direction. If the phallus is very small, there is a risk of losing it when transferring it from one container to another during staining and dehydration; in such a case, it is advisable to separate it from the genital capsule in a drop of Euparal on the slide immediately before mounting.

Since in many groups of Lepidoptera the shape of the vesica is complex and of high diagnostic significance, after eversion with water the vesica should be inflated by prolonged (3–7 seconds) injection of absolute isopropanol, which tans the membrane and preserves the vesica shape. Immediately after the procedure, place the phallus in the alcoholic dye solution. The stained phallus should subsequently be briefly rinsed in a container with absolute isopropanol and transferred to a pre-mounting container with Euparal.

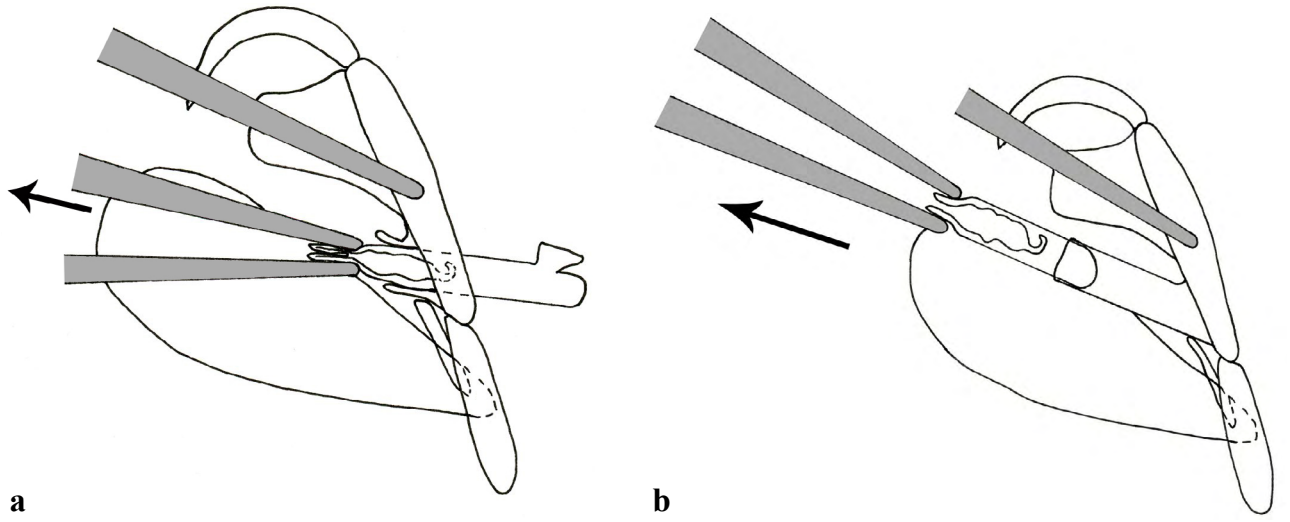

Figure 3. Dissection of male genitalia: removal of the phallus from the genital capsule by pulling it in a caudal direction (a), withdrawing it from the phallocrypt and everting the latter like a stocking (b).

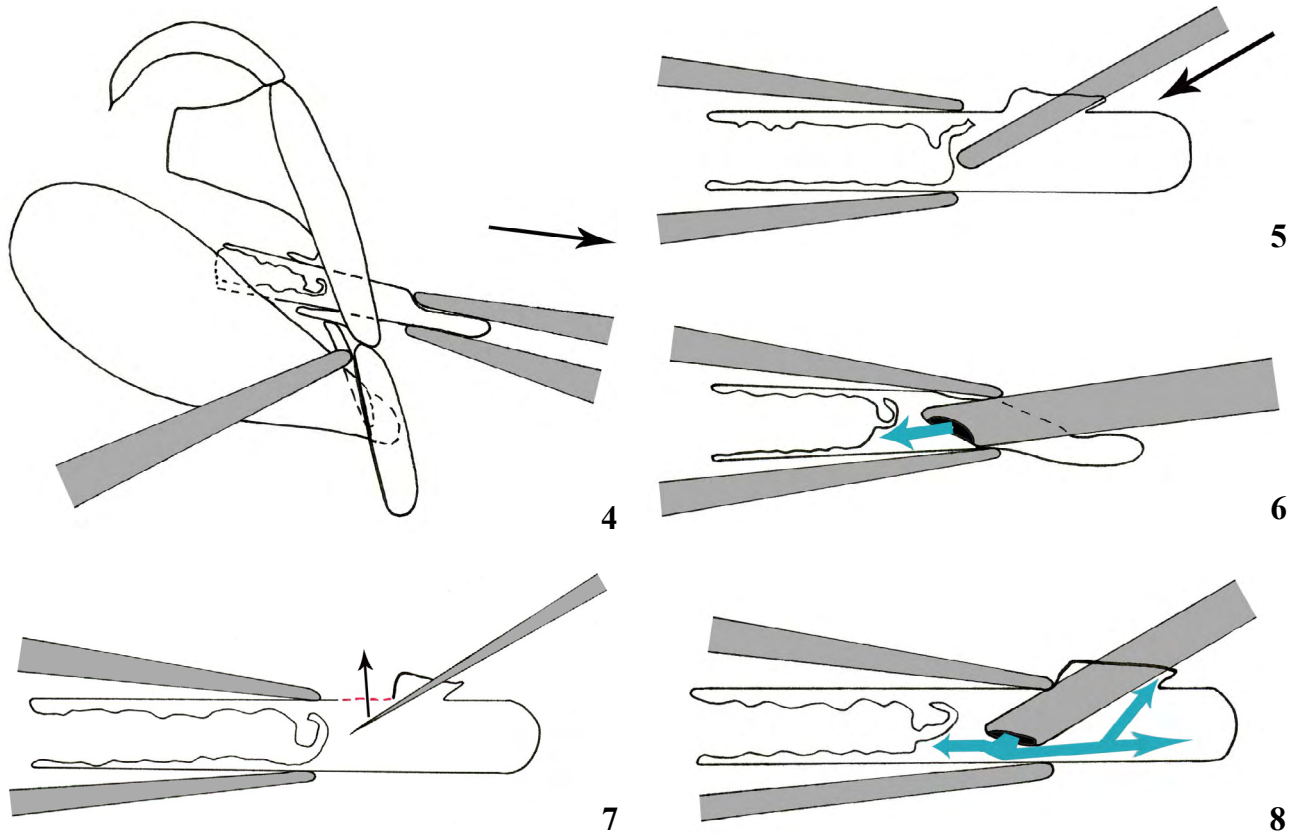

Figures 4–6. Dissection of male genitalia. **4.** Removal of the phallus from the genital capsule by pulling it in a cranial direction. **5**. Pushing the vesica forward with the blunt tip of a pin. **6**. Injection via a needle inserted into the phallus tube through the opening of the ductus ejaculatorius. **7.** Incision of the dorsal wall of the phallus tube caudal to the ductus ejaculatorius with the sharp tip of a pin in order to enlarge the entrance hole for the injection. **8**. Slow injection via a loosely inserted needle with a partial loss of the liquid pressure through the opening of the ductus ejaculatorius.

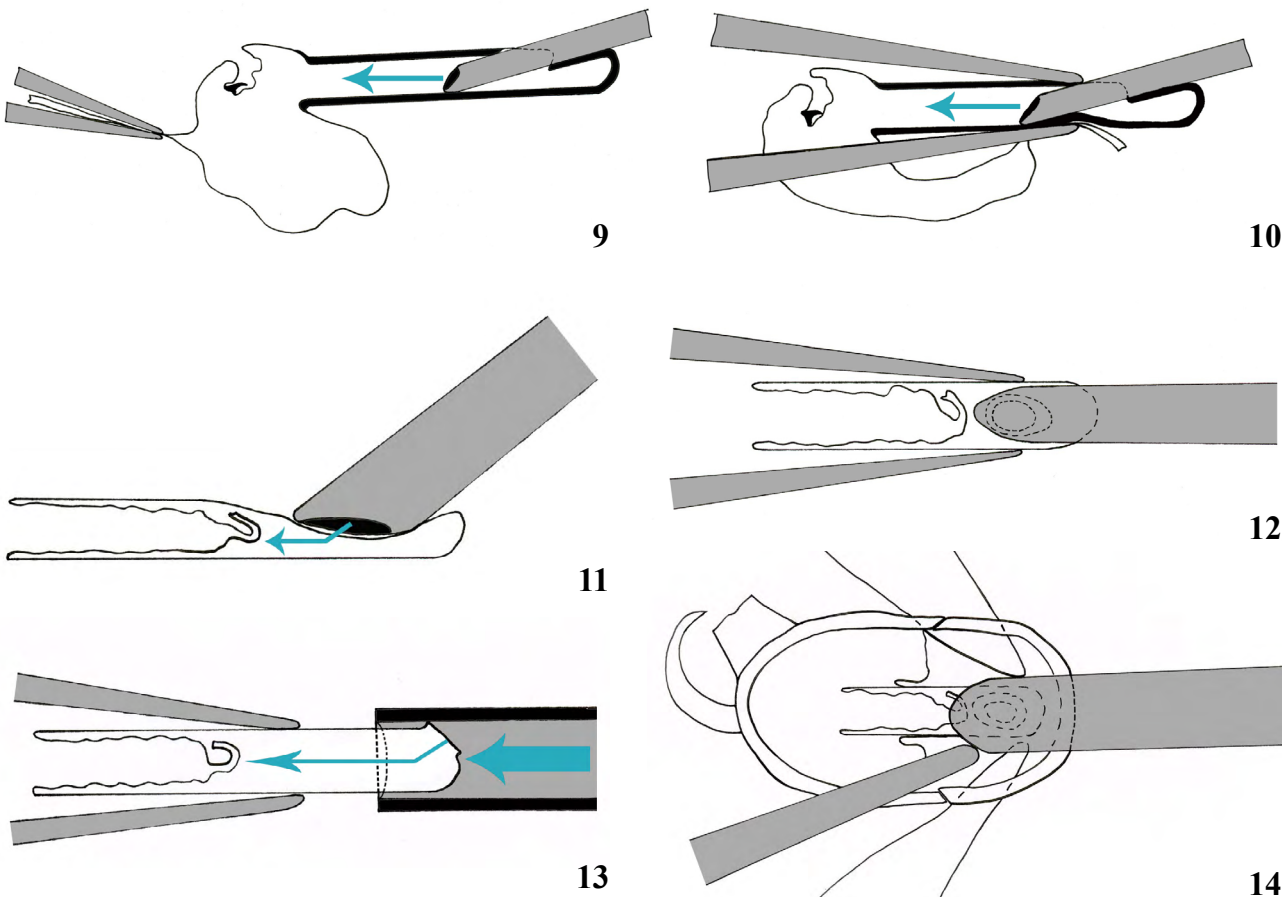

Figures 9–14. Dissection of male genitalia. **9**. Clamping of the vesica ejaculatorius with forceps in order to increase the liquid pressure and evert the not yet everted diverticulum. **10**. Clamping of the recurved vesica ejaculatorius via pressing it against the wall of the phallus tube and the syringe needle, in order to increase the liquid pressure and evert the not yet everted diverticulum. **11**. Injection into the small phallus directed from the outside the phallus tube via the syringe needle orifice pressed against the opening of the ductus ejaculatorius. **12**. Pressing the syringe needle orifice against the small phallus' ductus ejaculatorius opening from above (top view). **13**. Direction of a jet of liquid into the tiny phallus, which is inserted it into the blunt syringe needle channel of a larger diameter. **14**. Injection into the small phallus directed from the outside the phallus tube via the syringe needle orifice pressed against the opening of the ductus ejaculatorius. The phallus is not removed from the genital capsule (top view).

After removal of the phallus, the genital capsule must be cleaned of scales and remnants of soft tissues using the trimmed brush or feather, and the remnants of soft tissues and air bubbles inside the valvae and the anal tube should be blown out by injections of water. After cleaning, it is recommended to spread the valvae in the position in which they are intended to be mounted on the slide, so as to stretch the flexible membranous structures, which may harden and later be torn or broken after dehydration in alcohol before placement in Euparal.

If the genital capsule is heavily sclerotised and its spreading is difficult or may cause damage, it is strongly recommended to place it for some time in lactic acid, which considerably softens the sclerites and membranes. After this, the genital capsule should be rinsed in 10% alkali solution to neutralise the acid, and then washed free of alkali in water, including flushing the hollow structures with water by injection. Afterwards, it is recommended to spread the valvae in the position in which they are intended to be mounted on the slide, so as to stretch the flexible membranous structures.

Place the cleaned and spread genital capsule in the staining solution. Since prolonged exposure of sclerotised structures to absolute alcohol makes them brittle, it is recommended to stain the genital capsule in an aqueous dye solution. After staining, rinse the genital capsule in a container of isopropanol to remove the aqueous dye solution, and place it on a microscope slide in a drop of isopropanol for final cleaning of remnants of soft tissues and scales that were not visible when unstained. It is additionally advisable to flush the internal spaces of the valvae

and the anal tube of residual water by injections of isopropanol. After that, quickly rinse the genital capsule in a container of isopropanol and immediately place it into the pre-mounting container with Euparal, first removing excess isopropanol that would thin the Euparal by touching the preparation to a paper tissue.

Dissection of female genitalia

Place the abdomen on a microscope slide so that it rests on its ventral side (with the ostium facing downwards).

Cut one of the lateral sides of the abdomen with *Vannas* scissors along the line of the stigmata, reaching the articulation between the 7th and 8th segments (Figs 15a, 16a).

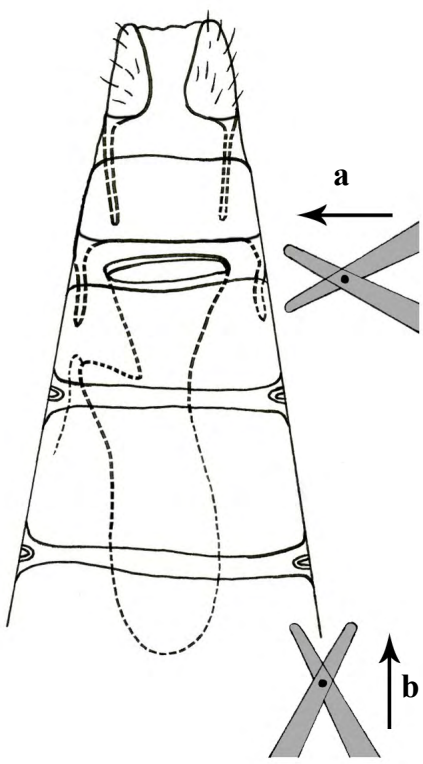

15

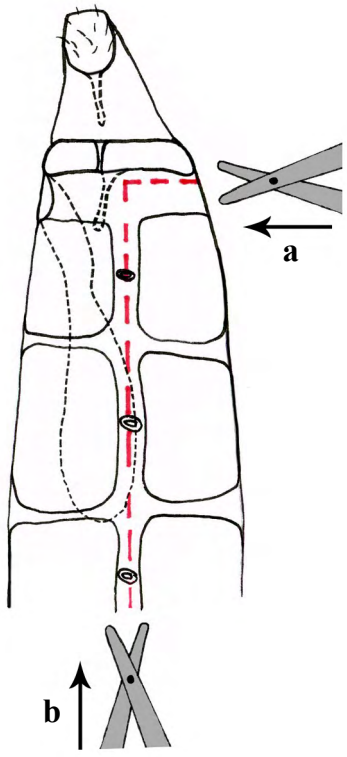

16

Figures 15, 16. Dissection of female genitalia. **15**. Directions for cutting the female abdomen exoskeleton using Vannas scissors (dorsal view): a) transversal cut of the dorsal intersegmental membrane posterior to the sternite VII; b) longitudinal cut along the stigmata. **16**. Directions for cutting the female abdomen exoskeleton using Vannas scissors (lateral view): a) transversal cut of the dorsal intersegmental membrane posterior to the 7th sternite; b) longitudinal cut along the stigmata.

Cut transversely through the dorsal section of the membrane connecting the 7th (abdominal) and 8th (genital) segments (Figs 15b, 16b), fold aside the dorsal part of the abdomen exoskeleton to open it, and remove the remnants of soft tissues, cleaning the intra-abdominal genital structures (Fig. 17: a). If the intra-abdominal genital structures are slender, membranous and difficult to distinguish from remnants of soft tissues, it is recommended to carry out a brief preliminary staining of the whole abdomen to make all membranous structures more visible. Additionally, injection through the ostium may help to expand the bursa and its appendix.

Turn the intra-abdominal genital structures outwards in the caudal direction, thereby opening access to the ventral side of the abdomen (Fig. 17: b).

If the anterior margin of the ostium is connected to the posterior margin of the 7th abdominal sternite by a membrane, and the structure and shape of the latter are not of diagnostic value, it is recommended to cut the genitalia off from the 7th abdominal sternite (Fig. 17: c). However, in many groups of Lepidoptera, the ostium is invaginated into the 7th sternite and/or rigidly articulated or fused with its posterior margin. In such cases, it is necessary to cut off the genitalia together with the 7th sternite from the rest of the abdomen (Fig. 17: d).

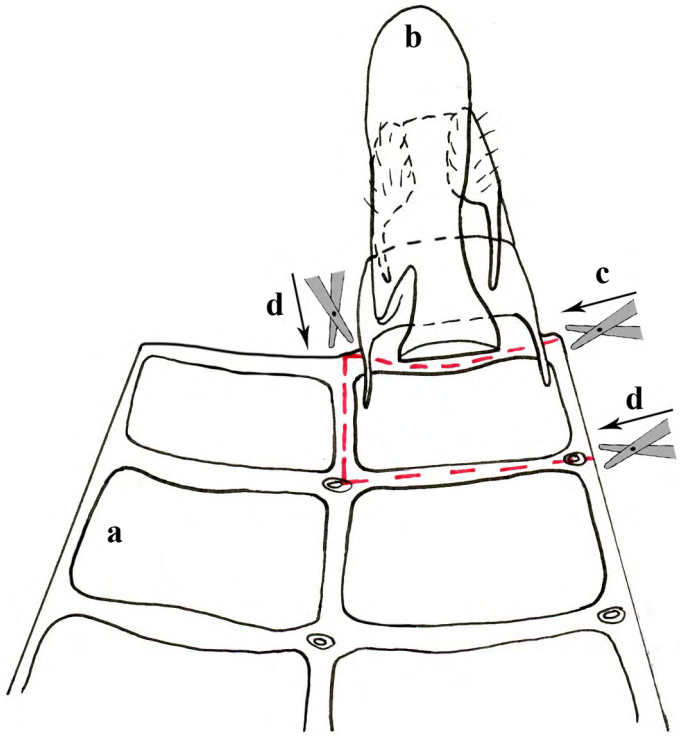

Figure 17. Dissection of female genitalia: cutting the female genitalia off the opened abdomen exoskeleton using Vannas scissors (ventral view): **a)** dorsal side of the abdomen folded aside; **b)** interior female genitalia turned in the caudal direction; **c)** direction for the transversal cut to detach the genitalia from the 7th sternite; **d)** directions for the cut to detach the genitalia from the abdomen together with the 7th sternite.

Place the isolated female genitalia on a microscope slide in a drop of water with the ostium facing upwards. While holding the ductus bursae with forceps, insert the syringe needle into it and make a prolonged injection of absolute isopropanol (Fig 18), which will expand and fix the corpus bursae and its appendix, as well as wash out remnants of soft tissues and the spermatophore through the ostium. Several injections may be required for complete cleaning. It is not uncommon for the bursa to contain an entire spermatophore or large fragments thereof that cannot be washed out through the ostium. In that case, a small tear or incision in the dorsal wall of the bursa is permissible, and the spermatophore can be removed with forceps or by intensive injection through the tear.

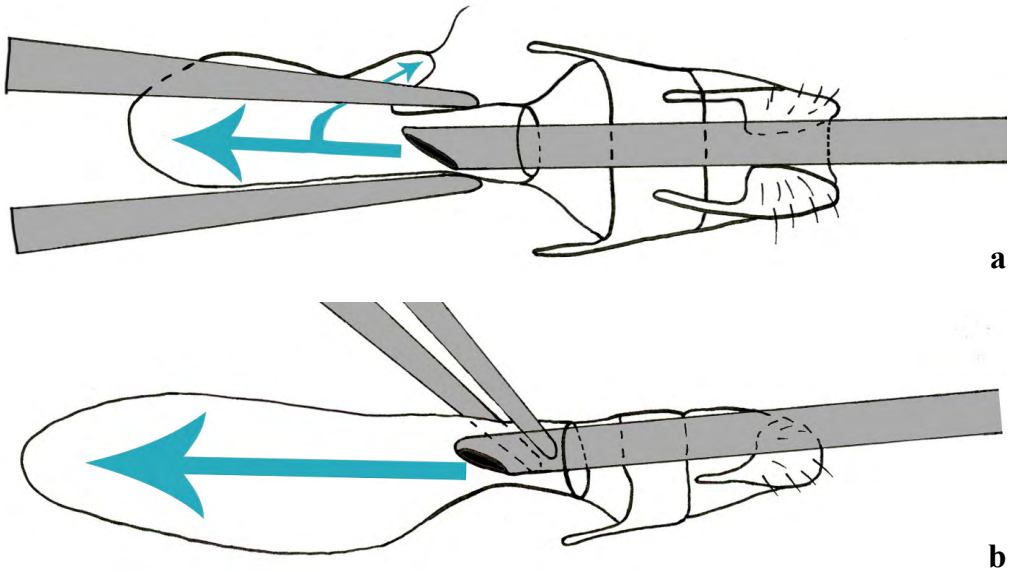

Figure 18. Injection with alcohol through the ostium bursae in order to spread the corpus and appendix bursae: **a)** ventral view; **b)** lateral view.

When the female genitalia are completely cleaned and rinsed, place them in the staining solution. After staining, rinse the genitalia in a container of isopropanol to remove excess dye, and place them on a microscope slide in a drop of isopropanol for final cleaning of remnants of soft tissues and scales that were not visible when unstained. Additional rinsing of the bursa by injection of isopropanol may also be needed. Upon completion of cleaning, place the stained female genitalia in a pre-mounting container with Euparal.

Dissection of the abdominal exoskeleton

Since the structure of the abdomen often has diagnostic value (both for species identification and for higher taxonomic purposes), it is recommended to preserve the exoskeleton (cuticle) of the abdomen and mount it on the slide next to the genitalia.

Clean the abdomen of scales using a brush or feather. In males, cleaning is more conveniently performed after removal of the genitalia. In females, it is better to remove most of the scales before dissection, so that the intra-abdominal genital structures can be seen during longitudinal cutting of the abdomen (see above for further details), thereby avoiding accidental damage to them. The male abdomen should also be cut open, which allows examination of the structure and shape of both sternites and tergites. After cleaning, place the abdomen in the alcoholic staining solution. If the abdomen is greasy, removal of scales may be problematic; therefore, it is first necessary to place the abdomen in a container of absolute isopropanol for a few minutes for degreasing. Repeated (final) cleaning is recommended after staining and rinsing in alcohol, when the remaining scales become easily removable and the remnants of soft tissues are clearly visible.

After cleaning and rinsing in isopropanol, place the stained abdomen in a pre-mounting container with Euparal, first touching it to a paper tissue to remove excess alcohol that would thin the Euparal.

Mounting, labelling and storage of the genital slides

Using a pipette, place 2–4 drops of Euparal in the centre of the slide. If the abdomen is large, it is recommended to mount it under a separate cover slip on one of the side thirds of the slide. The opposite third is left free for labelling.

Transfer the genitalia and the abdomen from pre-mounting container with Euparal into the drop(s) of Euparal on the slide. Spread the abdominal cuticle and all its structures with forceps.

Turn the genital capsule with its anterior side upwards, spread the valvae laterally, and press the capsule against the glass to spread the valvae fully and fix them in this position. If the uncus is flattened dorso-ventrally, spread it in the upward direction from the tegumen. If the uncus is flattened laterally, expose it in that position by bending the arms of the tegumen sideways and pressing them against the slide surface to fix them in place. Also expose the anal tube laterally so that the structure of the scaphium and subscaphium is visible. Turn the spread genital capsule with its posterior side (inner surface of the valvae) uppermost and spread the anellus if it is crumpled and its structure is not visible. Then turn the genital capsule back with its anterior side uppermost and press it lightly against the slide, leaving it in this position while working with the phallus.

If, owing to the specific structure of the genital capsule, the valvae cannot be spread, the genital capsule should be exposed laterally on the slide.

The phallus with the everted vesica should be positioned so that all diverticula and cornuti are maximally visible. To preserve the shape of the vesica and prevent it from being flattened by the cover slip, it is recommended to place next to it an object of thickness equal to or slightly greater than its own. This may be a piece of thick glass or plastic. The author of this paper usually uses a piece of fishing line. It is convenient to have several coils of fishing line of various diameters (0.5–1.5 mm) for genitalia of different sizes.

When the phallus has been placed in the desired position, turn the genital capsule with its posterior side uppermost and carefully cover all structures in the drop of Euparal with a cover slip, trying to avoid the formation of air bubbles. For this, it is convenient to place one edge of the cover slip on the slide and then gradually lower it towards the opposite edge, slowly covering the entire preparation. In contrast to the vesica, in most cases the genital capsule should be pressed firmly against the slide by the cover slip. Therefore, if fishing line/glass is used to preserve the shape of the vesica, it is sensible to place the phallus and the genital capsule under opposite sides of the same cover slip, or to place them under different cover slips (Fig. 19). In the first case, covering of the preparation with

the cover slip should be started from the side of the genital capsule. After covering, it may be necessary to add a few drops of Euparal from the side of the phallus and the object of thickness (e.g., fishing line) to ensure that the entire space under the cover slip is filled.

Mounting of female genitalia is similar to that of males. The genitalia should be positioned with the ostium uppermost to make the subostial structures readily visible. It is also necessary to spread the bursa and the appendix bursae, as well as to extend and spread the ovipositor. If the genitalia are voluminous and have a complex structure, it is strongly recommended, as with the male vesica, to avoid flattening by placing an object of thickness (e.g., a piece of fishing line) under the cover slip (Fig. 20).

The finished genital slide should be provided with a label indicating the generic and specific name of the dissected specimen, as well as the data from its geographical label (Figs 19, 20). Additionally, the label may include the type status of the specimen and the name of the preparator. To avoid confusion, it is strongly recommended to assign a unique number to the preparation, which should be indicated both on the preparation label and on a separate label pinned under the dissected specimen.

Slides stained with Eosin should be stored in the dark, as light fades the dye. During hardening, Euparal shrinks, so some time after preparation it is necessary to add more Euparal to the emerging margins using a pipette. Complete hardening of Euparal at room temperature requires a long time, also depending on the thickness of the Euparal layer. For this reason, it is recommended to store and transport the genital slides horizontally for the first few months after mounting. Hardening can be accelerated by drying at elevated temperatures (40–50 °C). For this purpose, specialised laboratory drying ovens, home food dehydrators, incubators, etc., may be used.

Instead of mounting on a slide, the genitalia may also be preserved in a micro vial with glycerol. The micro vial may be pinned under the dissected specimen or stored separately. In the latter case, a unique number must be assigned to the preparation and the specimen dissected.

Remounting of genital slides

There are occasions when it is necessary to dismount a slide, for example, if voluminous genitalia need to be placed and imaged from a different angle, or if the current quality of the preparation is unsatisfactory, making correct examination of the genitalia impossible. An example of the latter case is old slides mounted at a time when eversion of the vesica and spreading of the bursa by injection were not yet common practice. Remaking such preparations in accordance with modern standards is particularly important if they belong to primary types.

If the preparation is mounted in Euparal, dissolving the latter is easy by placing the slide in a test tube or Petri dish with absolute alcohol. Depending on the thickness of the Euparal layer and the age of the preparation, dissolution usually takes up to one day. Dismounting a preparation mounted in Canada balsam is more difficult and requires treatment with xylene. Manipulation with the latter requires observance of safety precautions because of its volatility and toxicity. It should also be borne in mind that the original label may be damaged.

It is recommended to subject the genitalia, once released from the mountant, to a brief (4–5 minutes) treatment with hot KOH and/or lactic acid to restore their flexibility. After this, the genitalia can be prepared, stained and remounted in the desired manner.

Conclusion

Examination of internal genital structures, such as the male vesica, provides the researcher with a significantly greater number of diagnostic characters that allow reliable identification of representatives of complicated taxonomic complexes exhibiting minor differences in the structure of external genitalia (genital capsules). It is particularly important that in series of preparations of similar specimens/species, voluminous structures, such as the male vesica and the female bursa copulatrix, are fully spread, their shape is fixed, and they are mounted on slides in similar positions. This allows detailed and accurate comparison of all homologous structures such as diverticula in the vesica, which is critically important for successful species identification. The author of this paper hopes that the methods and approaches described herein will be useful to researchers, including those specialising in small-sized Lepidoptera groups.

Acknowledgements

The author expresses his sincere thanks to Alexey Matov (St. Petersburg, Russia) and Dmitry Shovkoon (Ceske Budejovice, Czech Republic) for valuable discussions of the vesica eversion techniques in the past.

References

Baker, J.R. (1941) Chlorazol Black E as a vital dye. *Nature*, 147, 744. https://doi.org/10.1038/147744a0

Bolte, K.B. (1990) Guide to the Geometridae of Canada (Lepidoptera). VI. Subfamily Larentiinae. 1. Revision of the genus *Eupithecia*. *Memoirs of the Entomological Society of Canada*, 151, 1–253.

Cannon, H.G. (1937) A new biological stain for general purposes. *Nature*, 139, 549. https://doi.org/10.1038/139549a0

Caro, H. (1892) Ueber die Entwickelung der Theerfarben-Industrie. *Berichte der deutschen chemischen Gesellschaft (Referate, Patente, Nekrologe)*, 25, 955–1105. [in German] https://doi.org/10.1002/cber.18920250399

Cooksey, C. (2013) Quirks of dye nomenclature. 1. Evans blue. *Biotechnic & Histochemistry*, 89 (2), 111–113. https://doi.org/10.3109/10520295.2013.822560

Dang, P.T. (1993) Vesicas of selected tortricid and small lepidopterous species, with descriptions of new techniques of vesica eversion (Lepidoptera: Tortricidae, Oecophoridae, Gelechiidae and Nepticulidae). *Canadian Entomologist*, 125, 785–799.

Evans, H.M. & Schulemann, W. (1914) The action of vital stains belonging to the benzidine group. *Science*, 39 (1004), 443–454. https://doi.org/10.1126/science.39.1004.443

Fibiger, M. (1997) *Noctuidae Europaeae. Vol. 3. Noctuinae III*. Entomological Press, Sorø, 452 pp.

Hardwick, D.F. (1950) Preparation of slide mounts of lepidopterous genitalia. *Canadian Entomologist*, 82, 231–235.

Janse, A.J.T. (1932) *The moths of South Africa. Vol. 1. Sematuridae to Geometridae*. E. P. & Commercial Printing Co., Durban, XI + 376 pp., XV pls.

Kononenko, V.S. (2010) *Noctuidae Sibiricae. Vol. 2. Micronoctuidae, Noctuidae: Rivulinae–Agaristinae (Lepidoptera)*. Entomological Press, Sorø, 475 pp.

Lafontaine, J. D. (1987) Noctuoidea. Noctuidae (part). *In*: Dominick, R.B. *et al.* (Eds), *The Moths of America North of Mexico, Fascicle 27 (2)*. The Wedge Entomological Research Foundation, Washington, pp. 1–237.

Lafontaine, J.D. & Mikkola, K. (1987) Las-och-nyckel systemen i de inre genitalierna av Noctuidae (Lepidoptera) som taksonomiska kaennetecken. [Lock-and-key systems in the inner genitalia of Noctuidae (Lepidoptera) as a taxonomic character.] *Entomologiske Meddelelser*, 55, 161–167. [In Swedish with English summary]

Mikkola, K. (2007) The rise of eversion techniques in lepidopteran taxonomy (Insecta: Lepidoptera). *SHILAP Revista de Lepidopterología*, 35 (139), 335–345. [https://www.redalyc.org/pdf/455/45513910.pdf]

Rambur, M.P. (1838–1842) *Faune Entomologique de l'Andalousie*. Bertrand, Paris, 336 pp. [1838: 1–96; 1839: 97–176; 1840: 177–304; 1842: 305–335] [in French]

Suvarna, S.K., Layton, S. & Bankroft, J.D. (Eds) (2013) *Bancroft's Theory and Practice of Histological Techniques (7th Edition)*. Churchill Living Stone, Edinburg, London, Melbourne, 604 pp.